

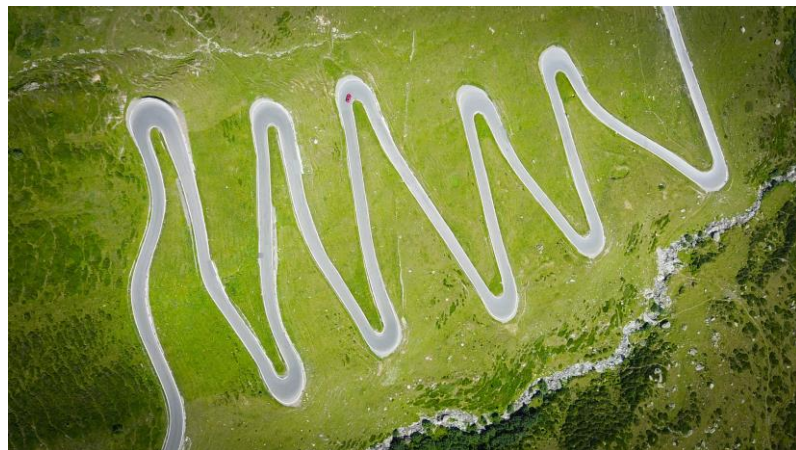Retinoblastoma bilateral: un largo camino

Jaume Català-Mora

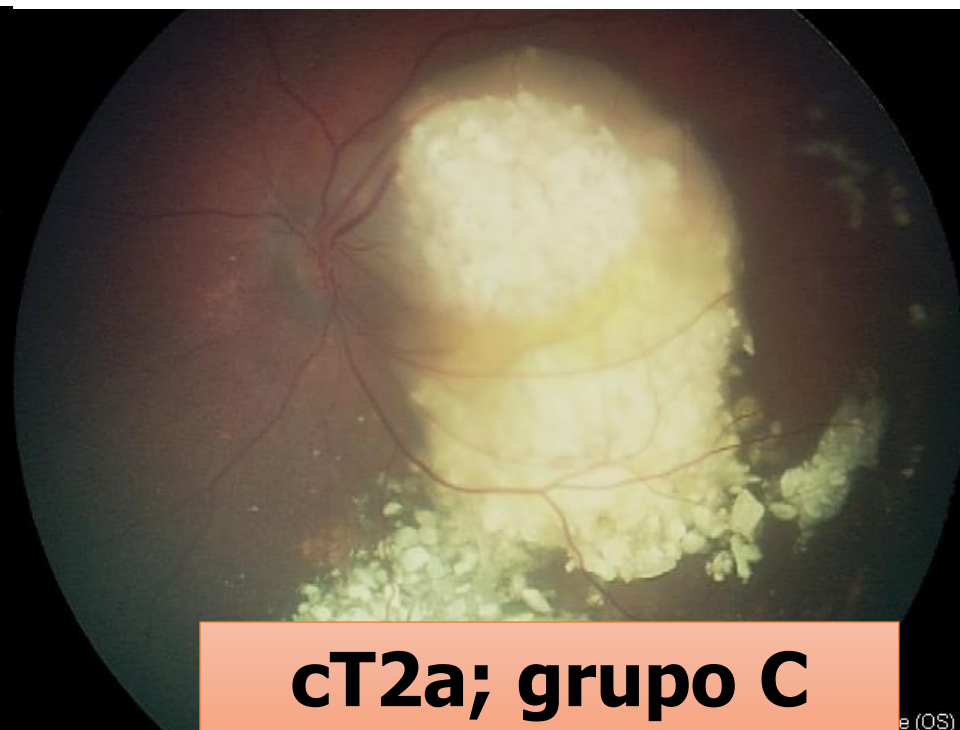
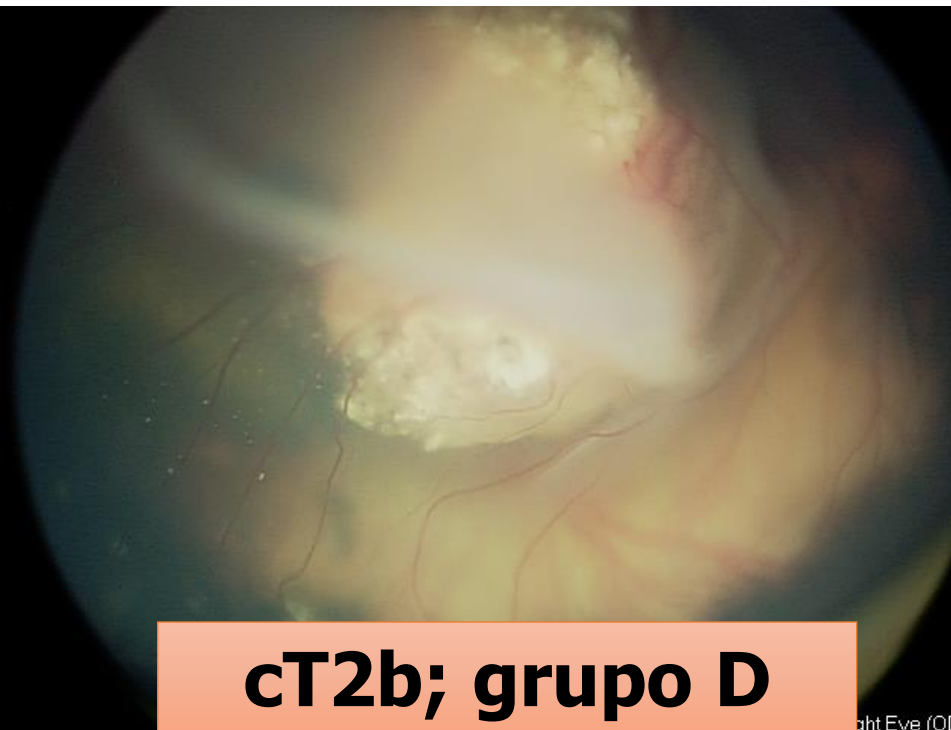Jesús Díaz Cascajosa, Alicia López de Eguileta,

Margarida Simao

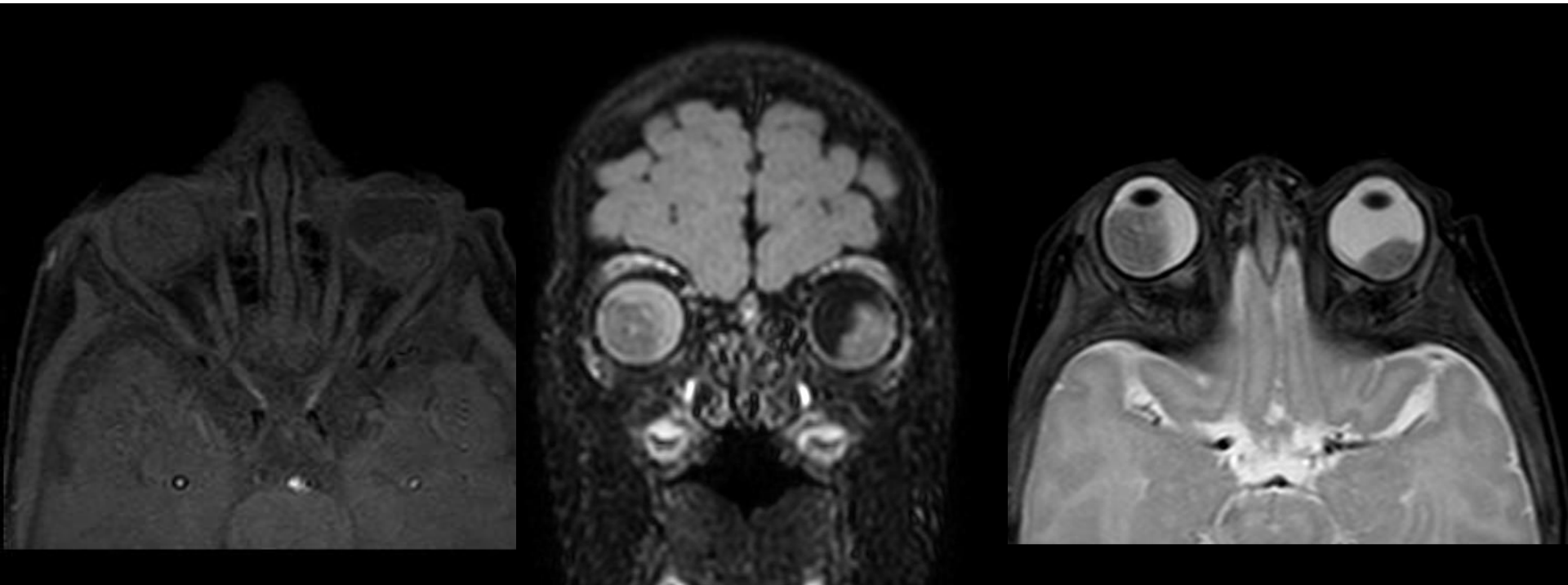
Primavera 2023



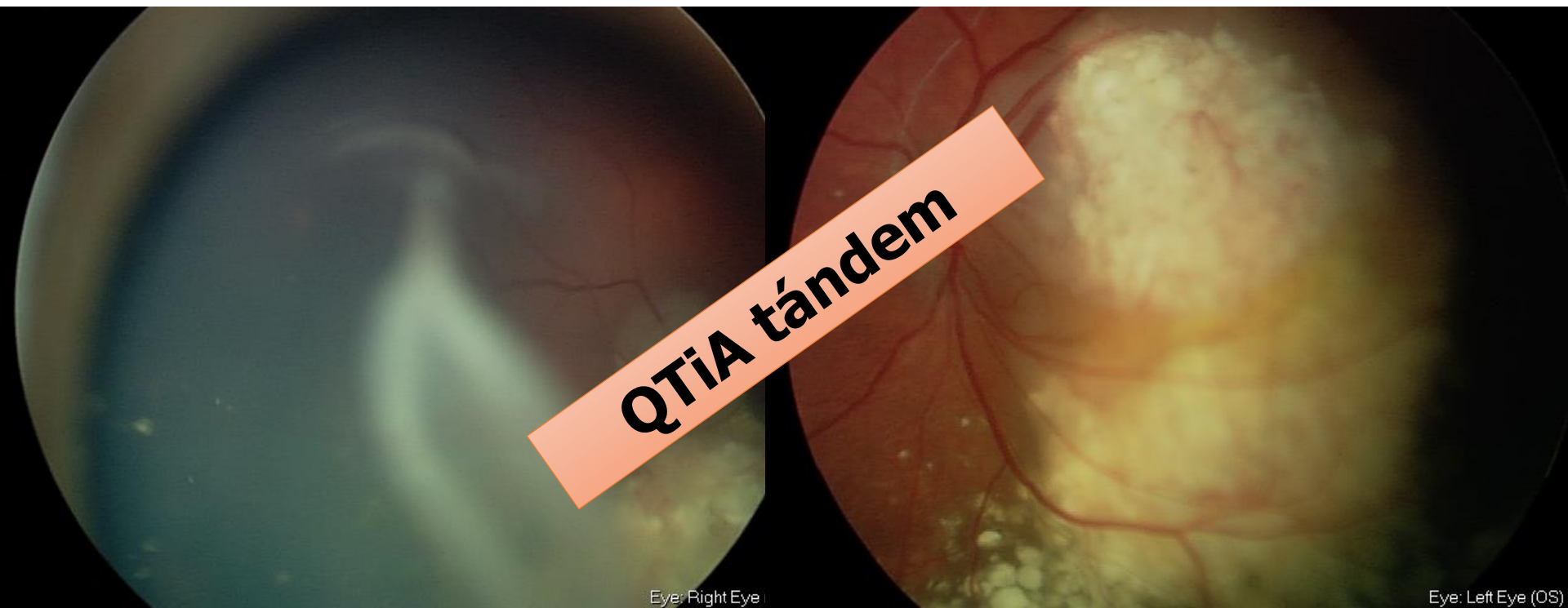
♂ **3 m Leucocoria ojo derecho**



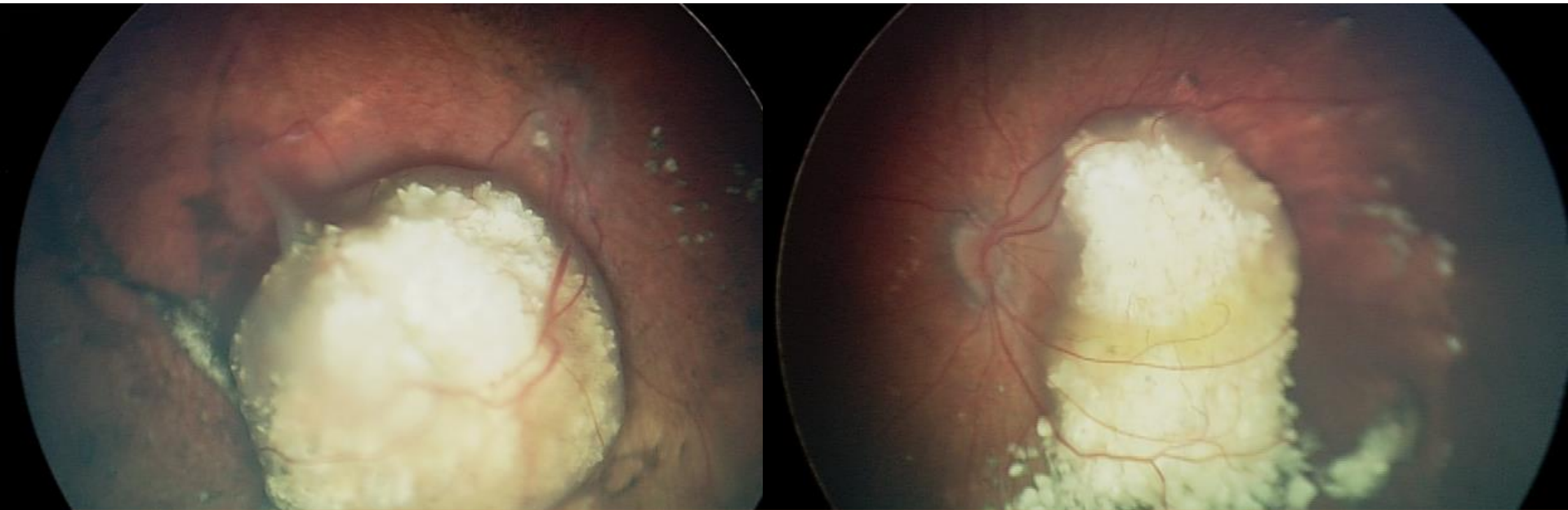
—
♂ **3 m Leucocoria ojo derecho**



QT sistemica (CBP)

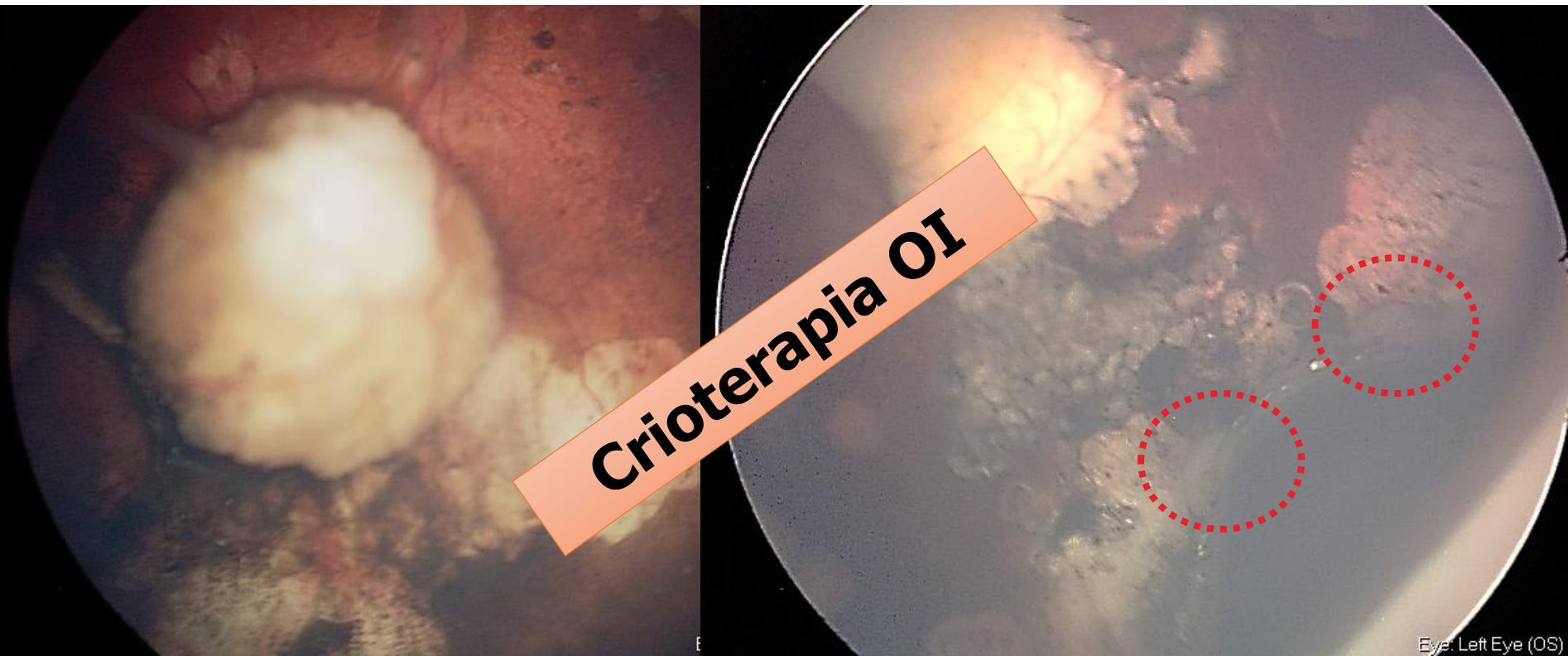


X1 QT sistémica, x1 IAC AO TTT AO



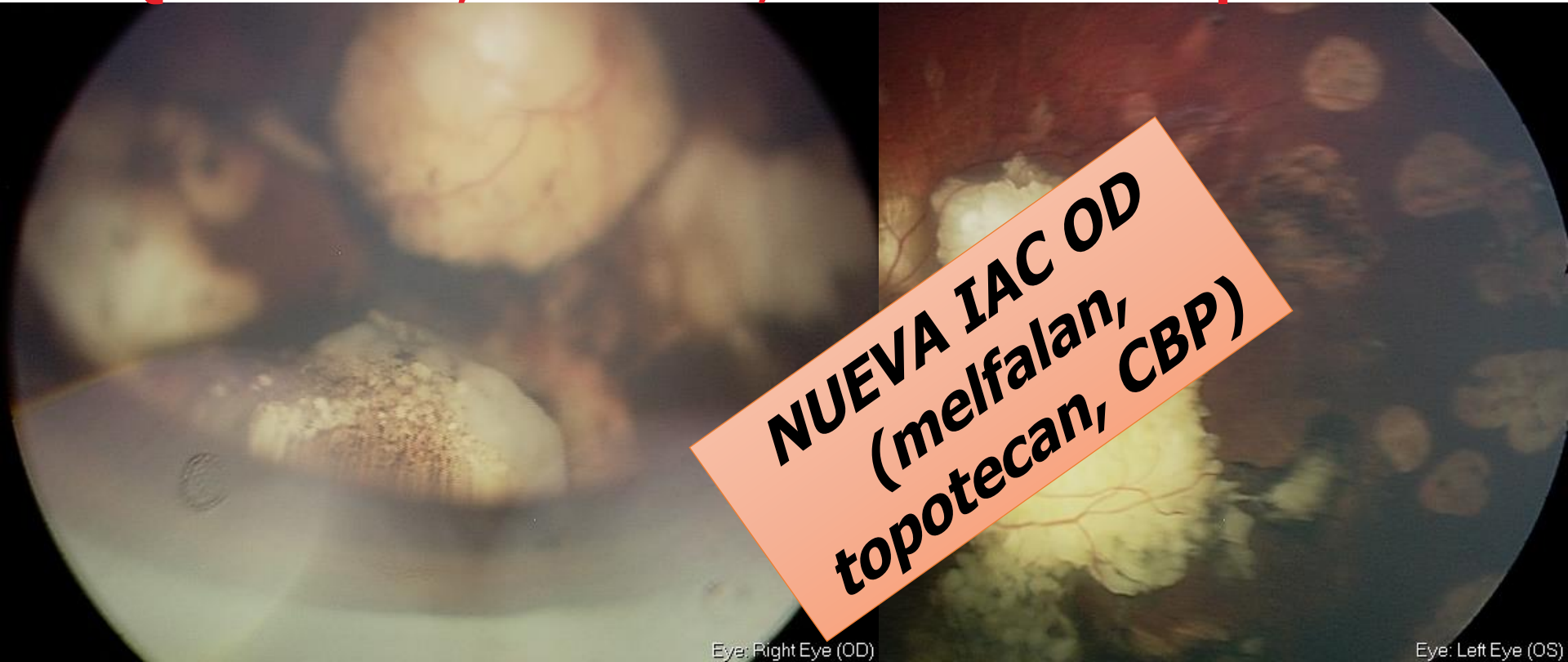
RB1 (NM_000321.2): p.Glu746fs/c.2237_2241delAAGAG

X1 QT sistémica, x4 IAC AO; TTT AO



Crioterapia OI

X1 QT sistémica, x6 IAC AO; TTT AO crioterapia AO

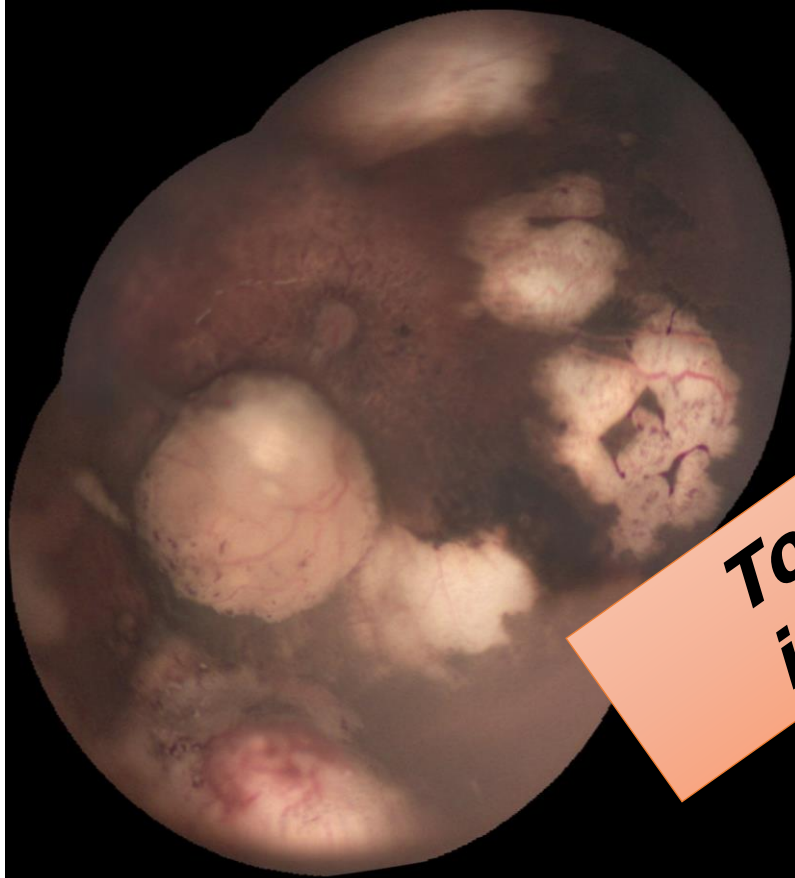


**NUEVA IAC OD
(melfalan,
topotecan, CBP)**

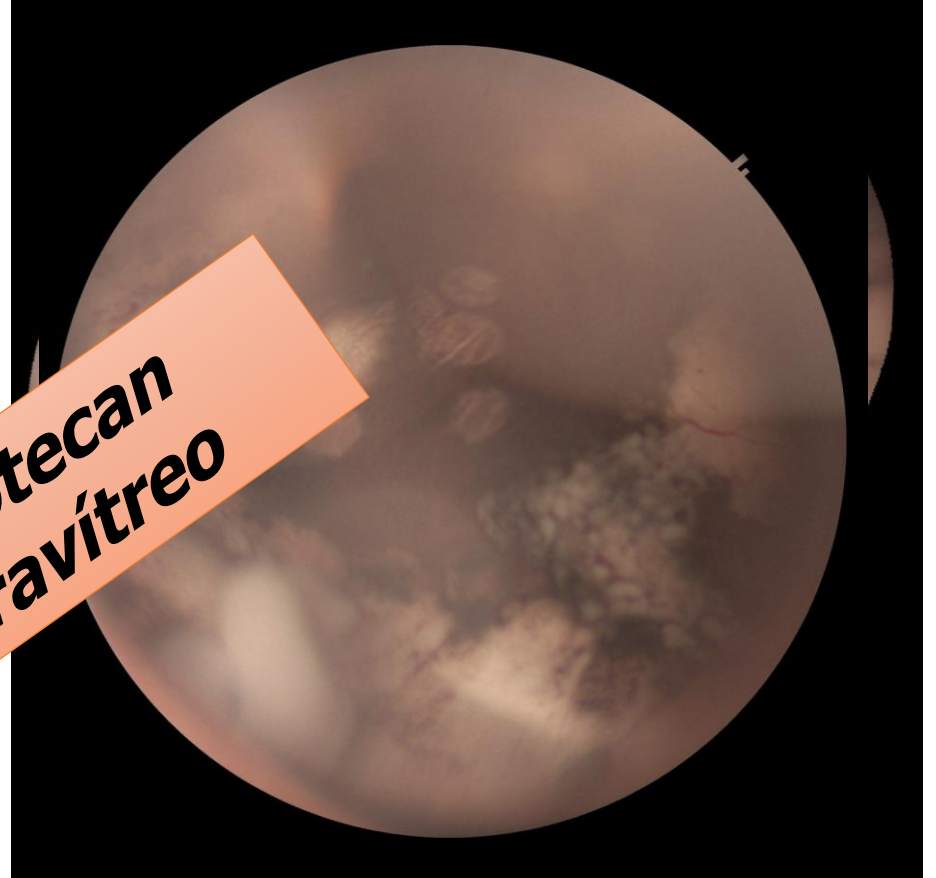
Eye: Right Eye (OD)

Eye: Left Eye (OS)

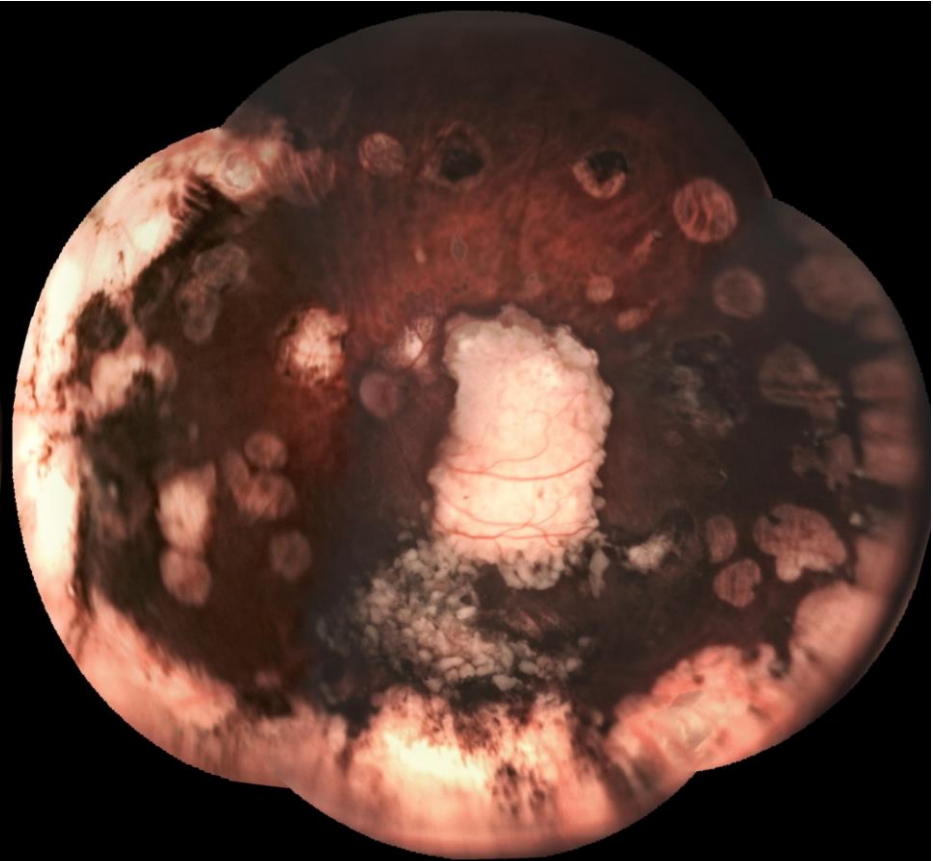
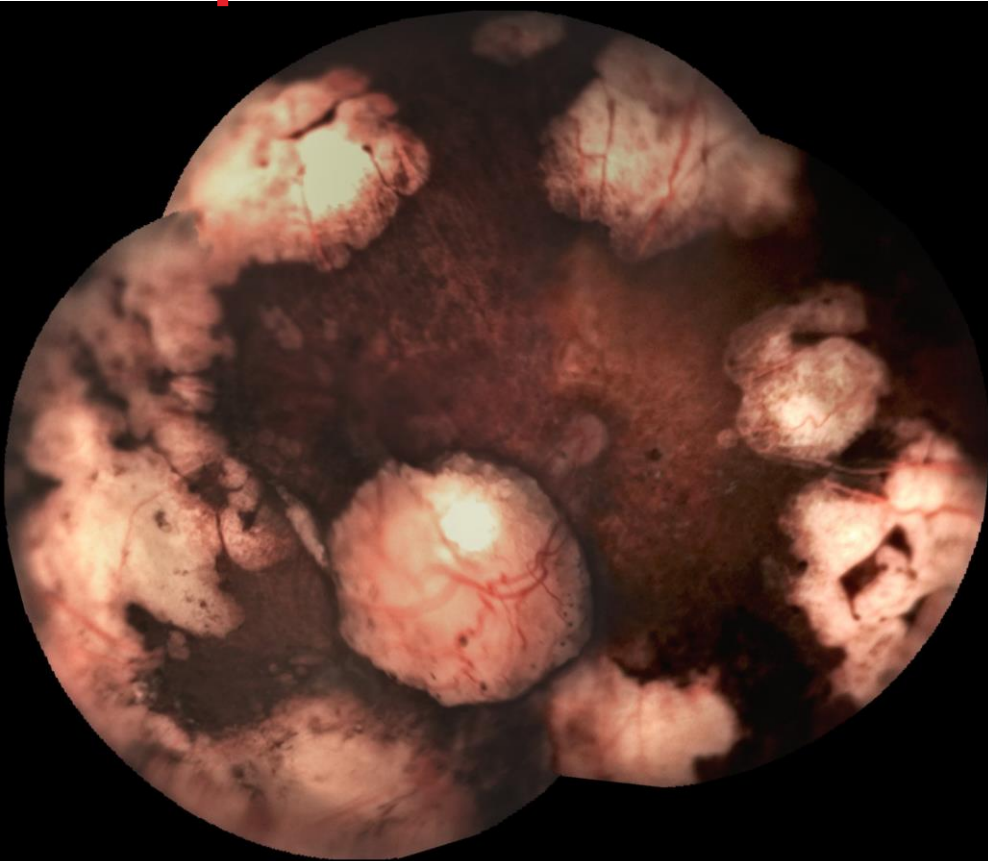
X1 QT sistémica, x7 IAC AO; TTT AO crioterapia AO

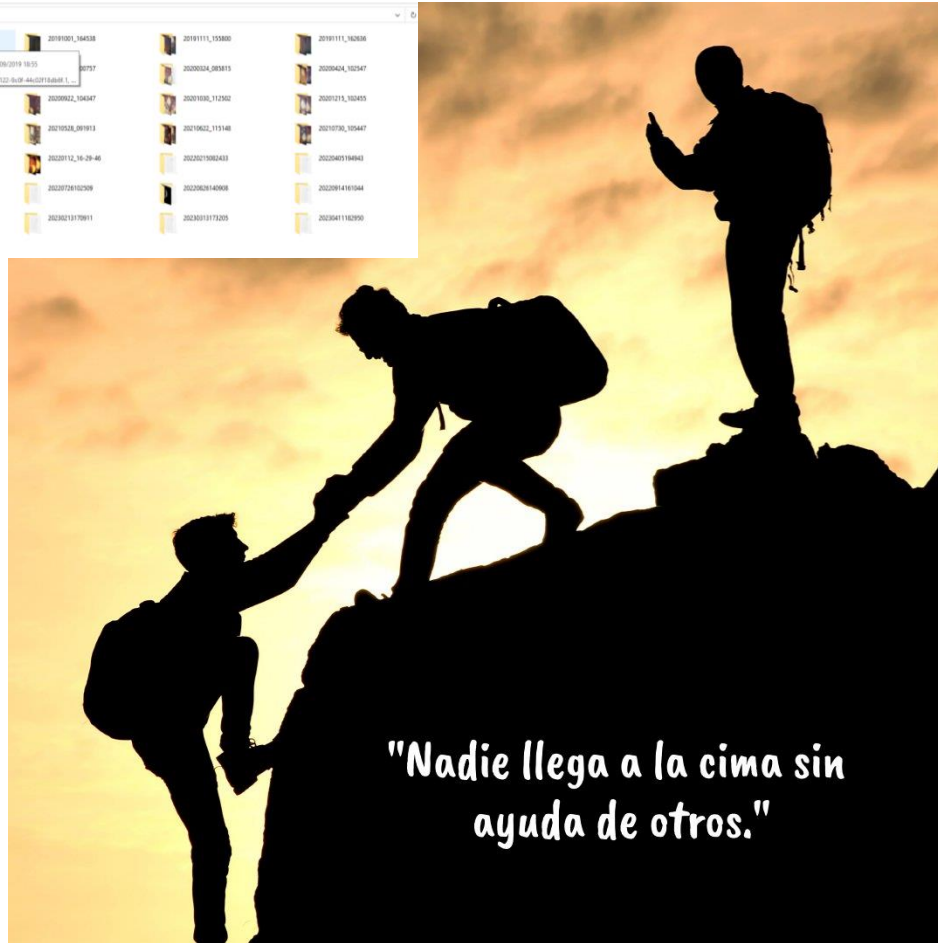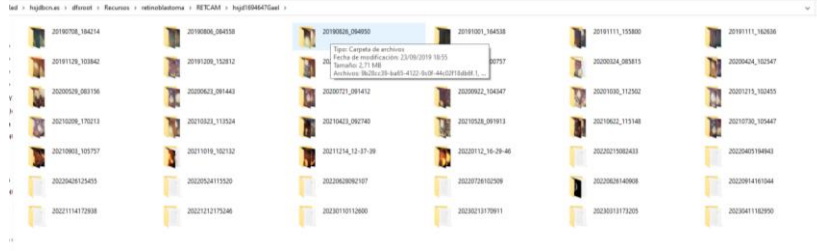


**Topotecan
intravítreo**



**X1 QT sistémica, x7 IAC AO; TTT AO crioterapia AO;
x4 topotecan intravítreo**







Gracias

Unitat tumors intraoculars pediàtrics SJD